

EyeRounds.org

Band Keratopathy

Category(ies): Cornea

Contributor: [Jesse Vislisel, MD](#)

[Brice, Critser, CRA](#)

Calcific band keratopathy (BK) results from calcium hydroxyapatite deposition in the superficial cornea, mainly Bowman layer. It can be caused by chronic ocular inflammation, hypercalcemia, hyperphosphatemia, chronic exposure to mercurial vapors or preservatives, silicone oil, primary hereditary transmission. It is often idiopathic. BK usually begins as fine, yellow-white deposits in the periphery that may coalesce over time to form a horizontal band across the cornea.

Figure 1.

Calcific band keratopathy secondary to hyperparathyroidism

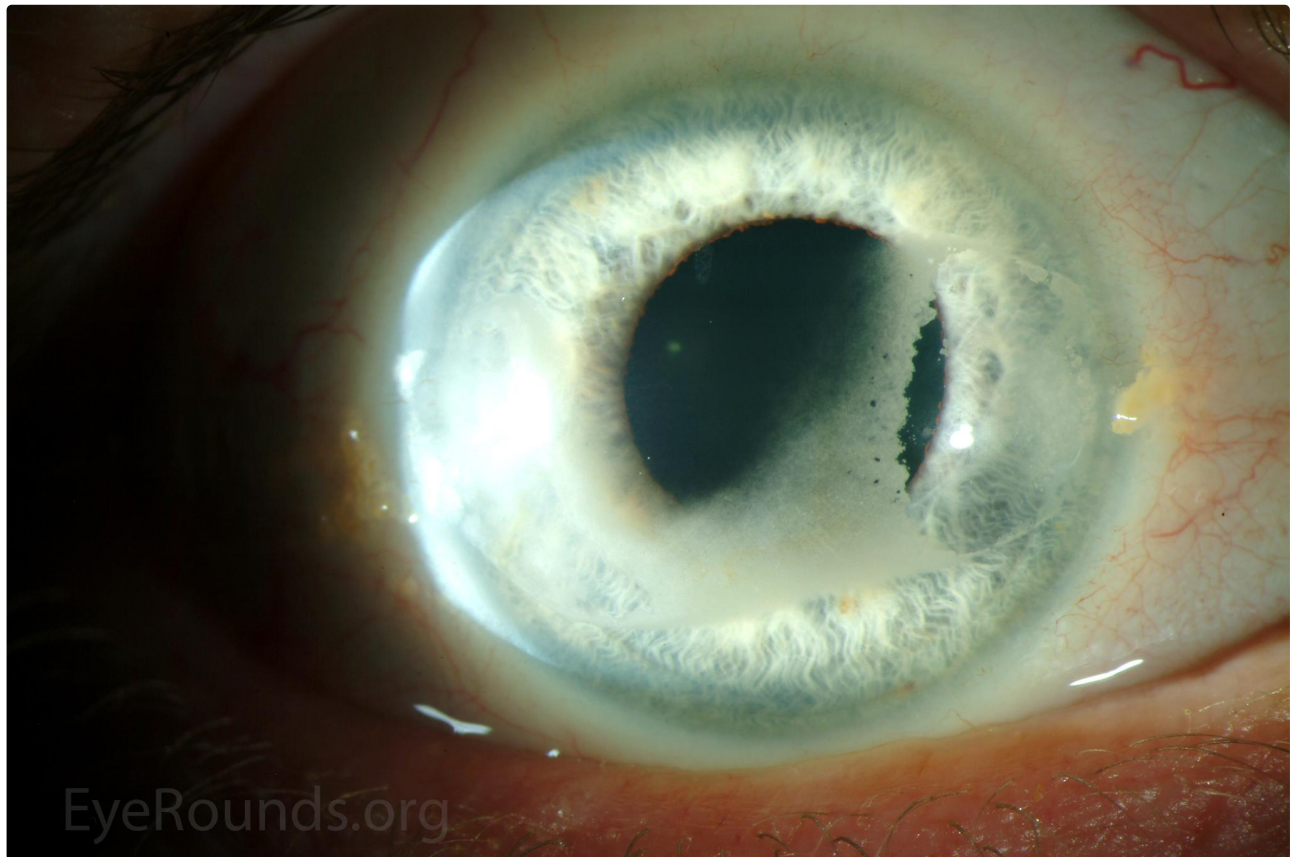


Figure 1-A

 Enlarge

 Download

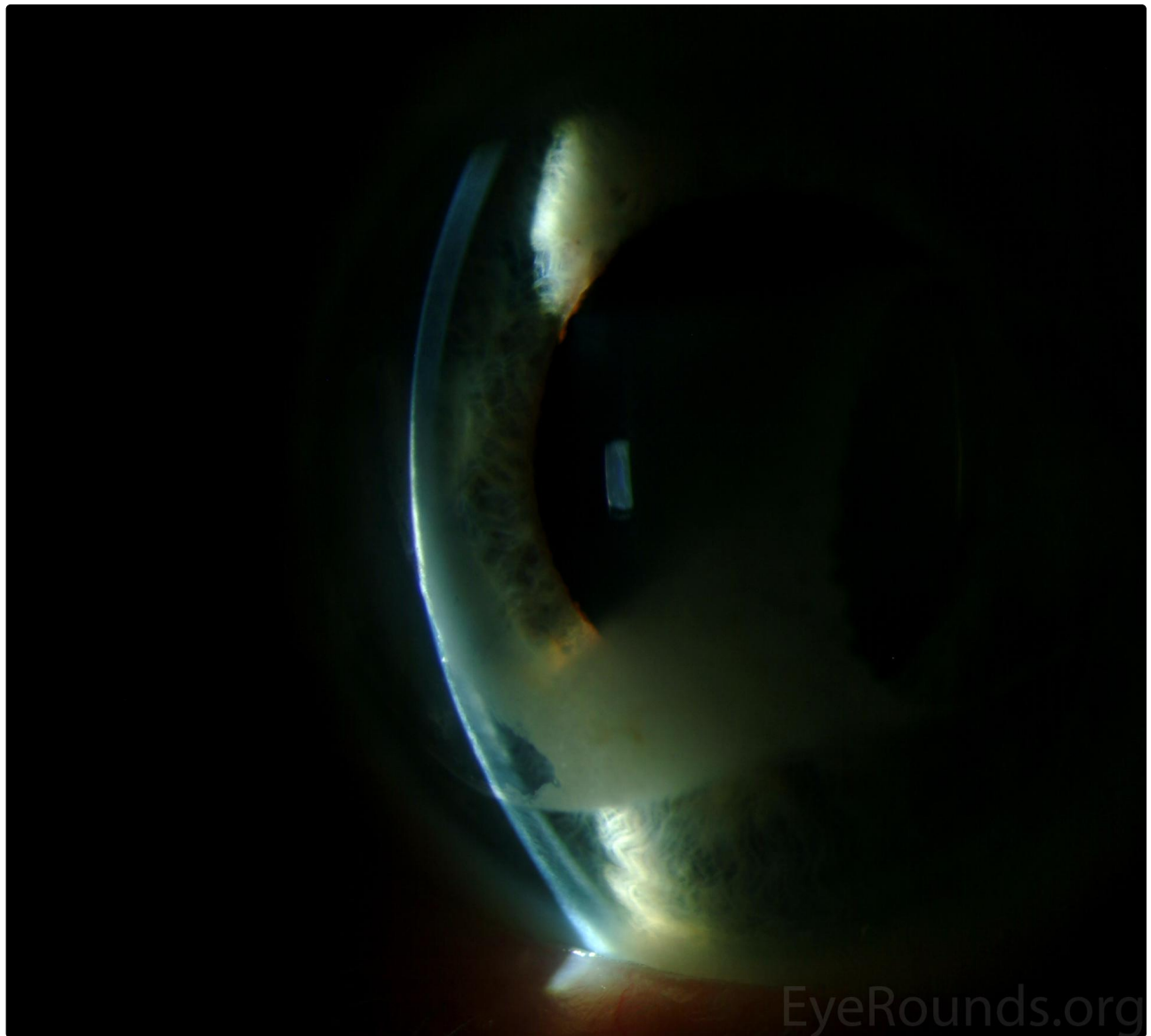
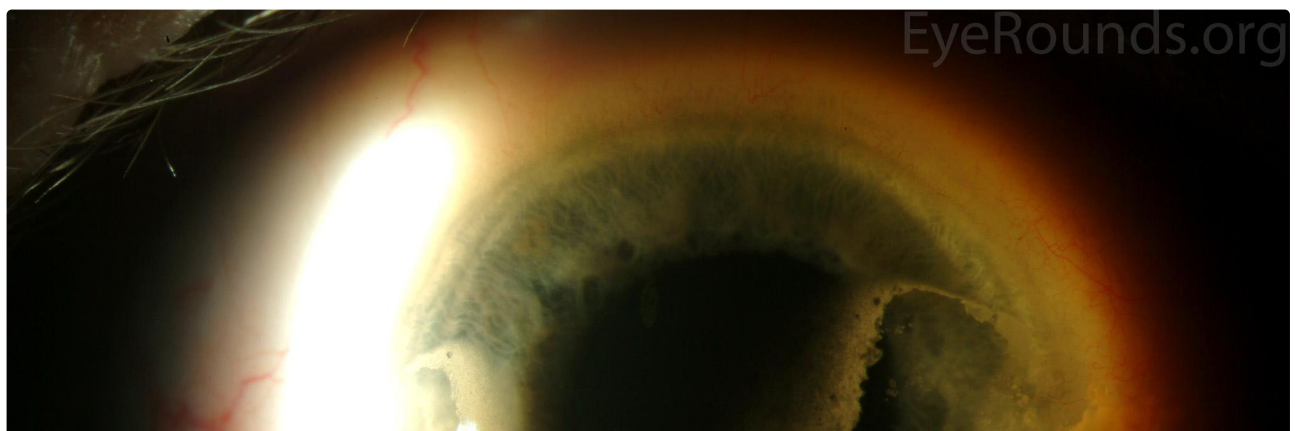


Figure 1-B

[Enlarge](#)

[Download](#)



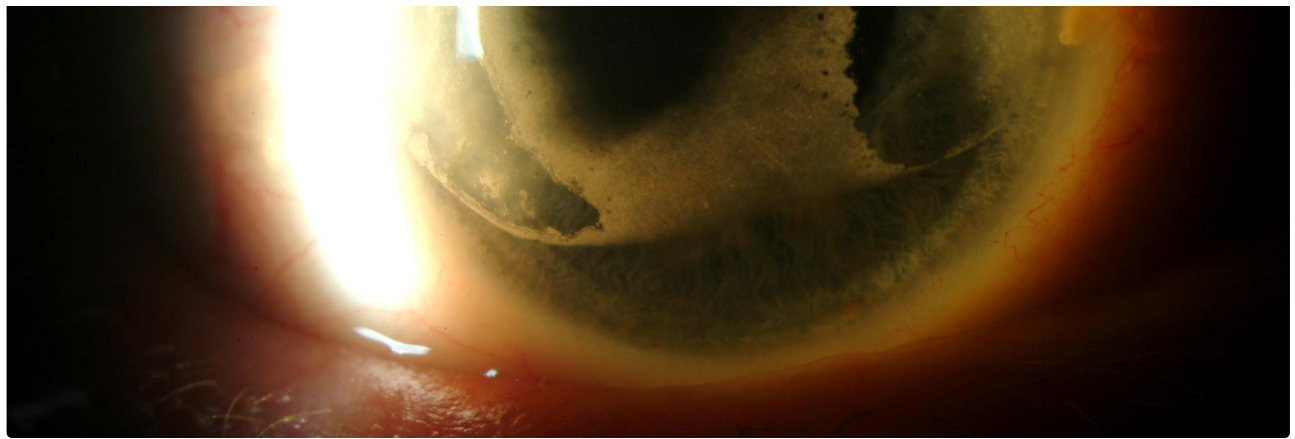


Figure 1-C

[Enlarge](#)

[Download](#)

Figure 2.

Early band keratopathy in a patient with uveitis associated with juvenile idiopathic arthritis. The accompanying iron line denotes the chronicity of these corneal changes.

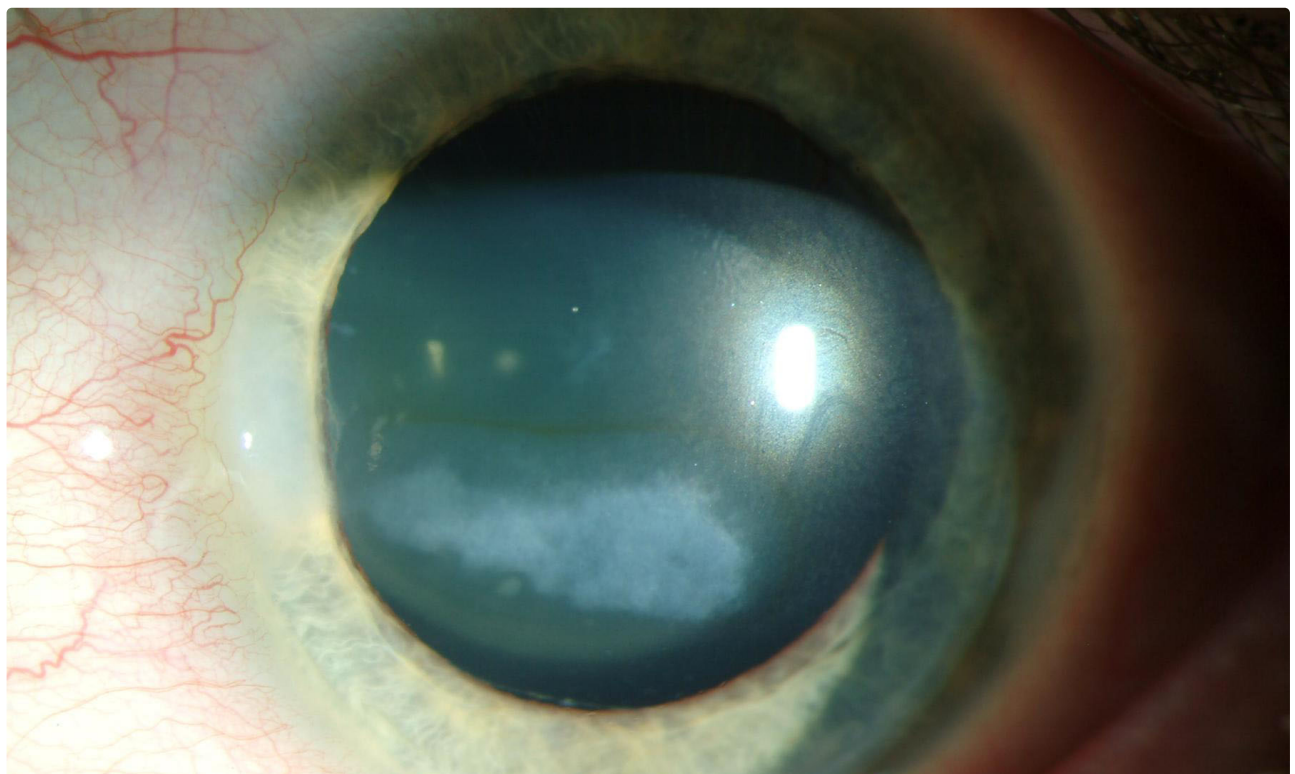




Figure 2-A

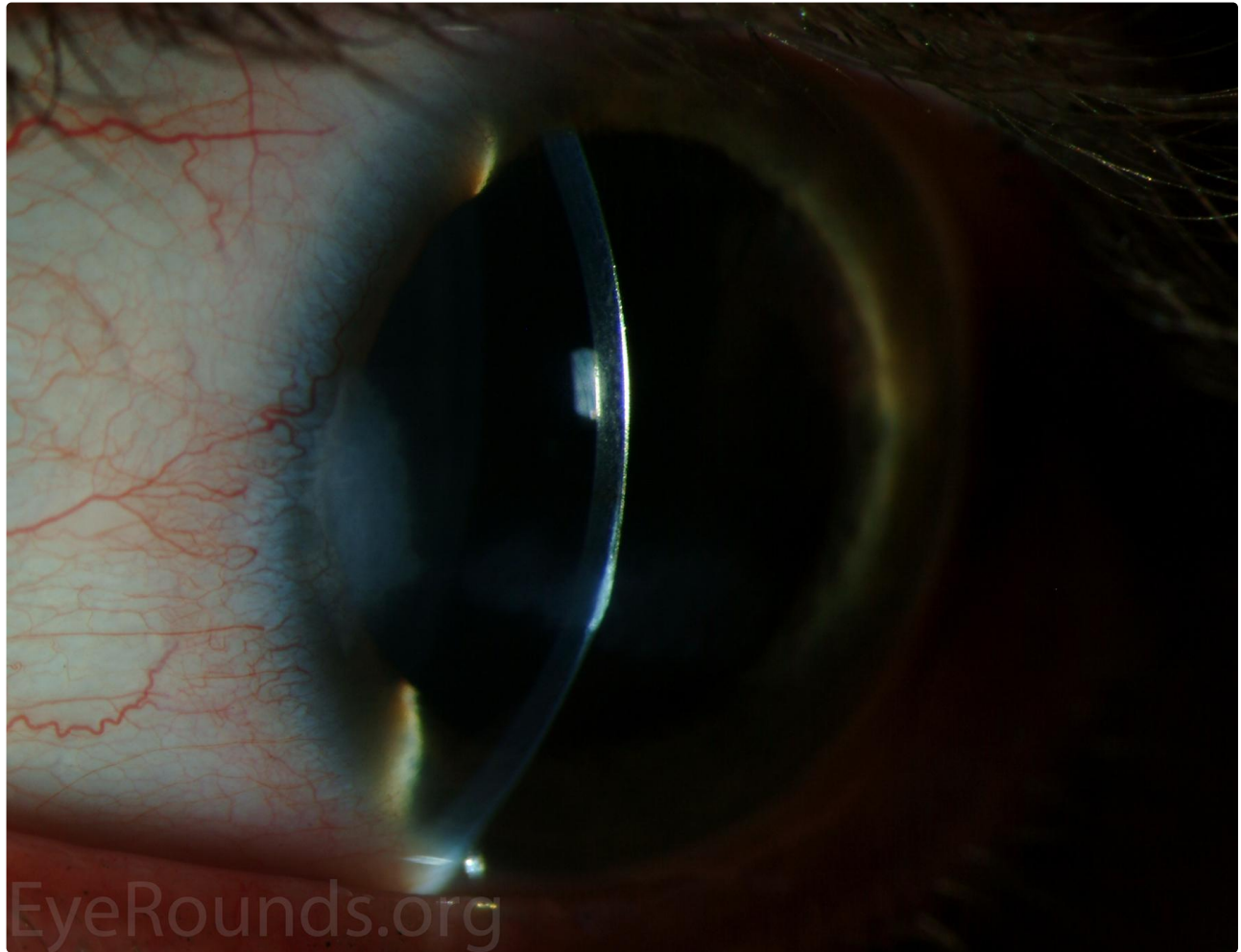


Figure 2-B



Figure 3.

Late band keratopathy with a chalky, white consistency.

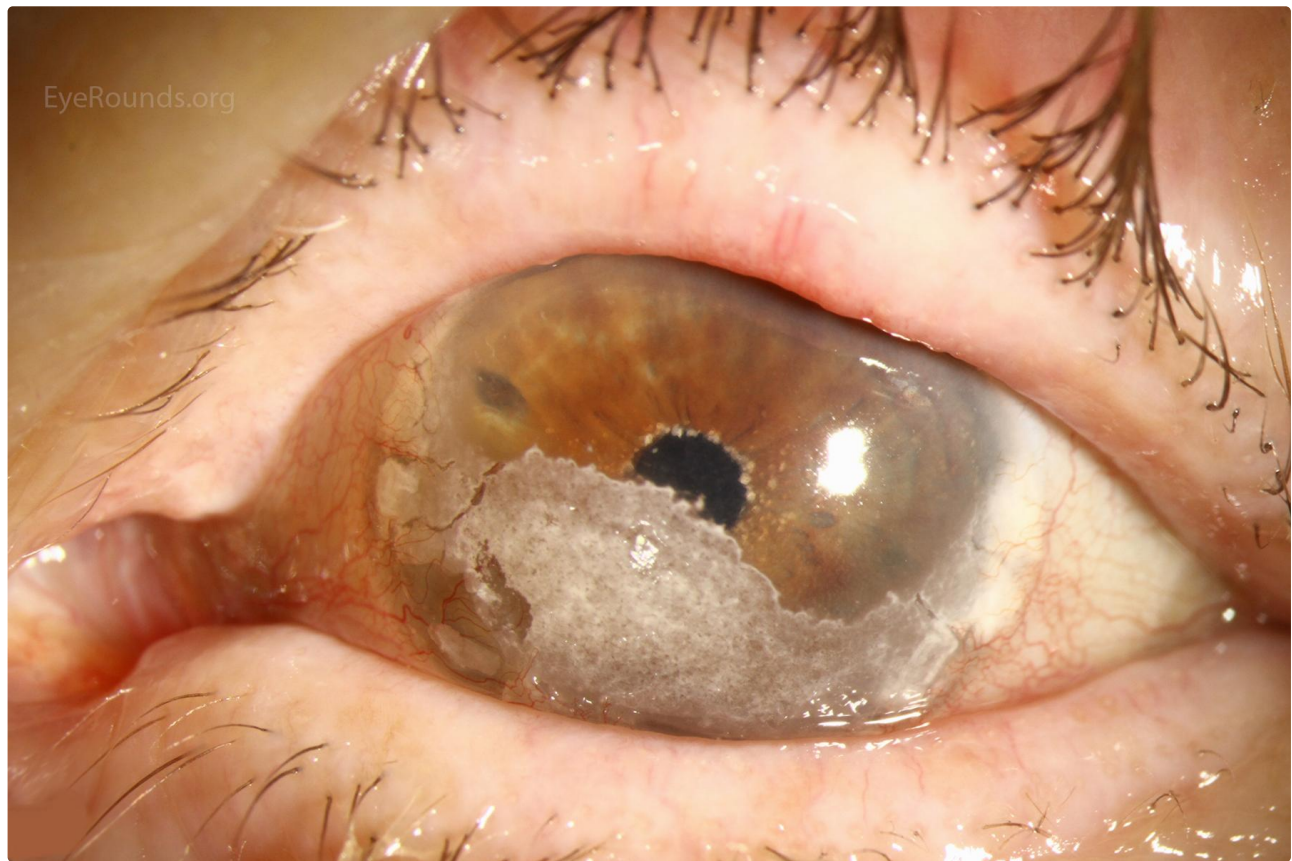


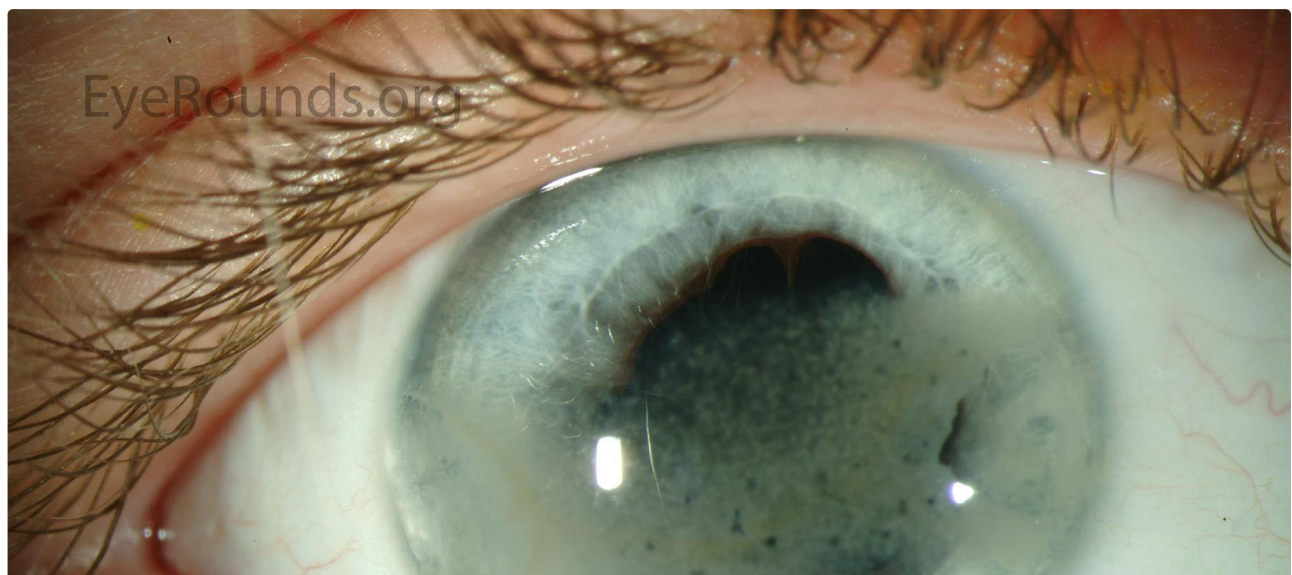Figure 3

[Enlarge](#)

[Download](#)

Figure 4.

Band keratopathy in a patient with HLA-B27-associated anterior uveitis. The "Swiss cheese" appearance derives from lucent "holes" in the calcific pattern due to corneal nerve penetration through Bowman's layer.



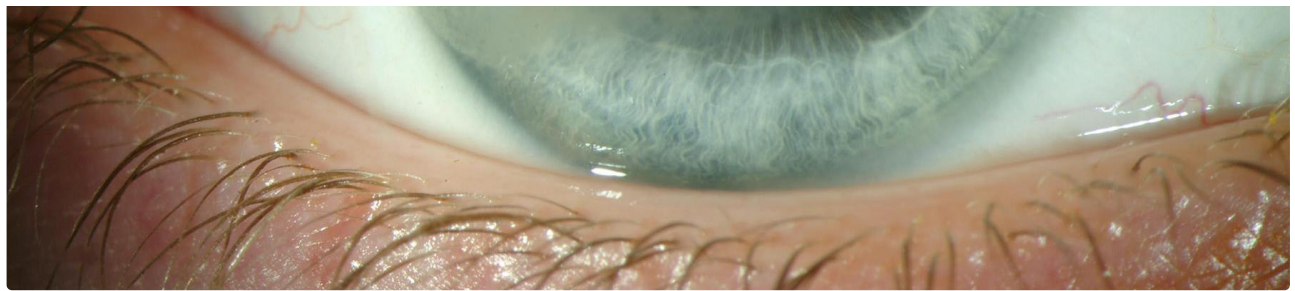


Figure 4-A

[Enlarge](#)

[Download](#)

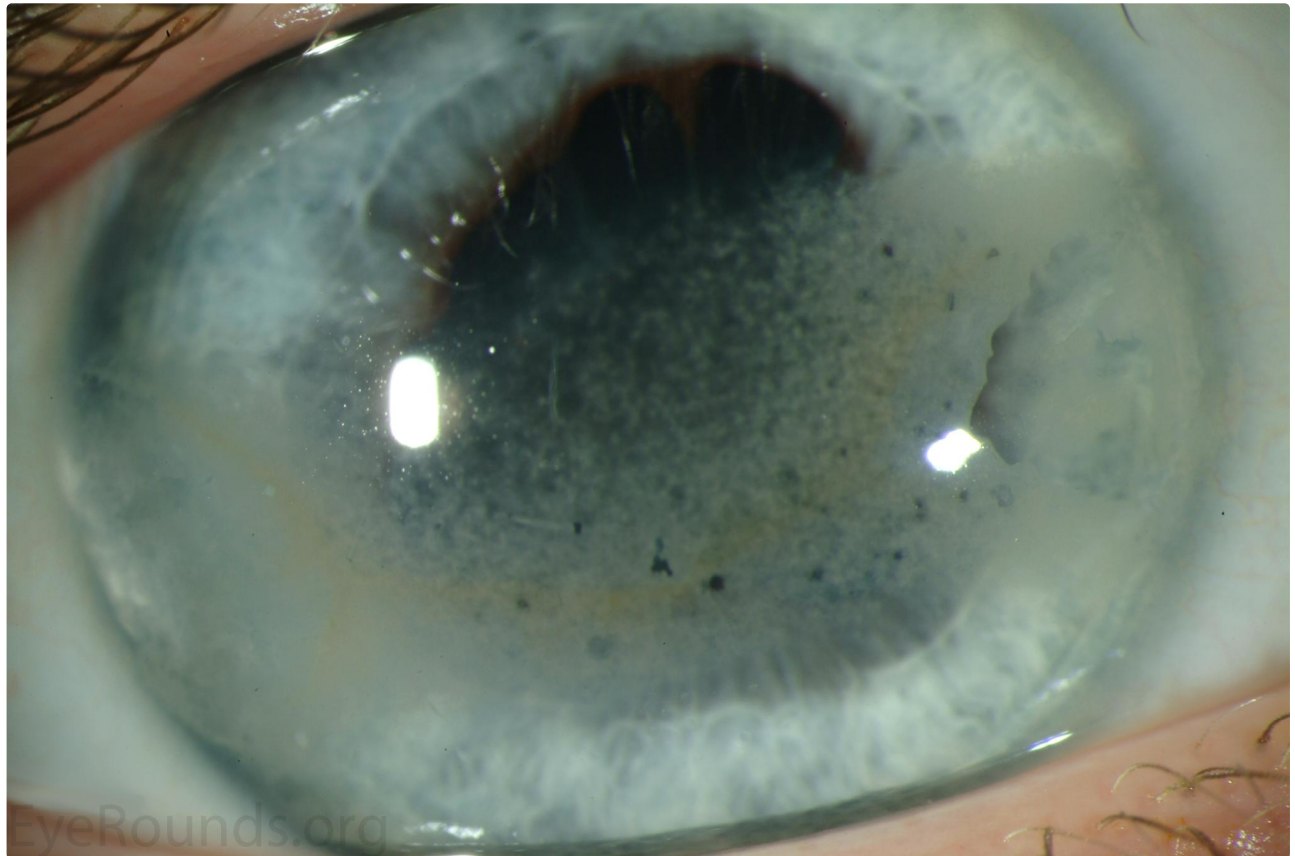

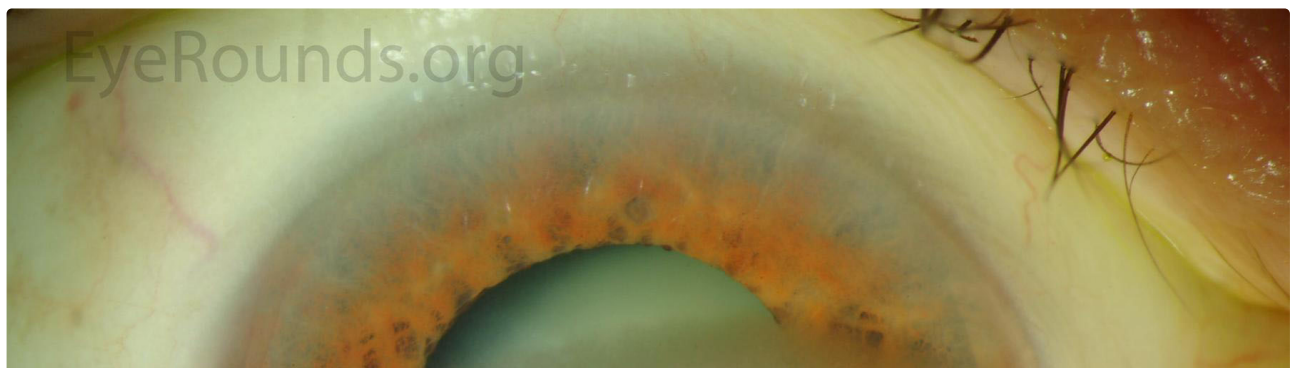
Figure 4-B

[Enlarge](#)

[Download](#)

Figure 5.

Calcific band keratopathy



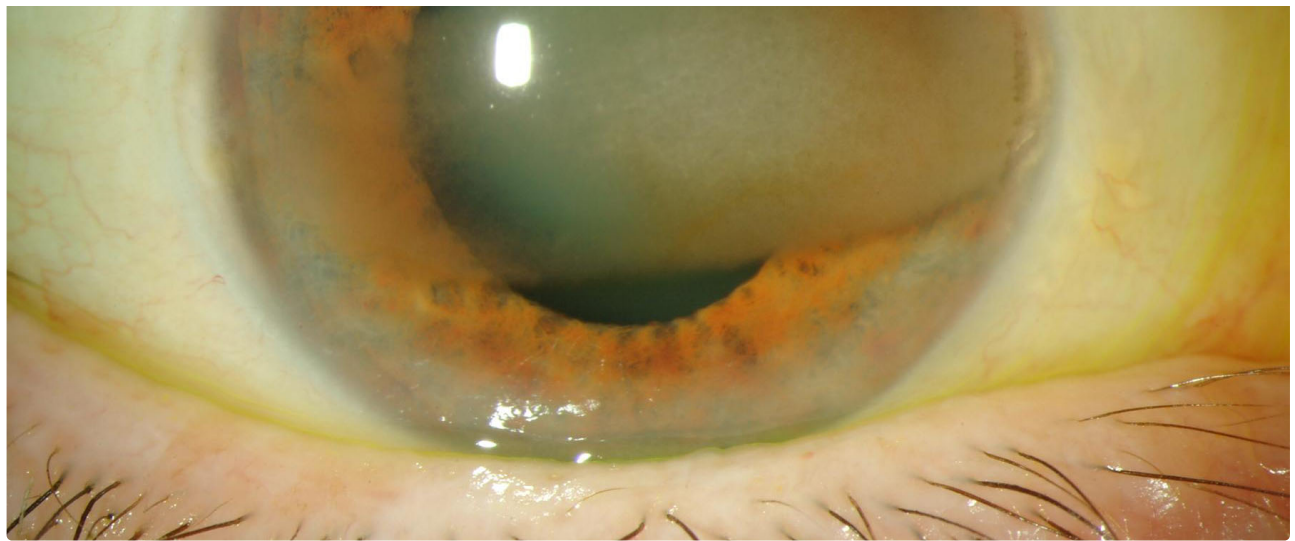


Figure 4-B

 Enlarge

 Download

Image Permissions:



Ophthalmic Atlas Images by [EyeRounds.org](https://www.eyerounds.org), [The University of Iowa](https://www.theuniversityofiowa.edu) are licensed under a [Creative Commons Attribution-NonCommercial-NoDerivs 3.0 Unported License](https://creativecommons.org/licenses/by-nc-nd/3.0/).



Related Articles

Address

University of Iowa
Roy J. and Lucille A. Carver College
of Medicine
Department of Ophthalmology and
Visual Sciences
200 Hawkins Drive
Iowa City, IA 52242

[Support Us](#)

Legal

Copyright © 2019 The University of
Iowa. All Rights Reserved
[Report an issue with this page](#)
[Web Privacy Policy](#) |
[Nondiscrimination Statement](#)

Related Links

[Cataract Surgery for Greenhorns](#)
[EyeTransillumination](#)
[Gonioscopy.org](#)
[Iowa Glaucoma Curriculum](#)
[Iowa Wet Lab](#)
[Patient Information](#)
[Stone Rounds](#)
[The Best Hits Bookshelf](#)

EyeRounds Social Media

Follow



Receive notification of new cases,
[sign up here](#)
[Contact Us](#)
[Submit a Suggestion](#)